

Simultaneous implantation and augmentation of a buccal bone defect with biologised bone substitute material

Dr Haki Tekyatan, Germany

In implant dentistry, we need sufficient bone and soft tissue for long-term and prognostically safe stability. This is a good prerequisite for long-term success in order to achieve secure stability of the implant and the surrounding peri-implant soft tissue. Buccal defects are often found in our practice and are frequently caused by physiological remodelling processes after tooth extraction. These remodelling processes after tooth loss are scientifically very well studied and proved. Especially the loss and degradation of the bundle bone results in a wide variety of defect morphologies.¹⁻³

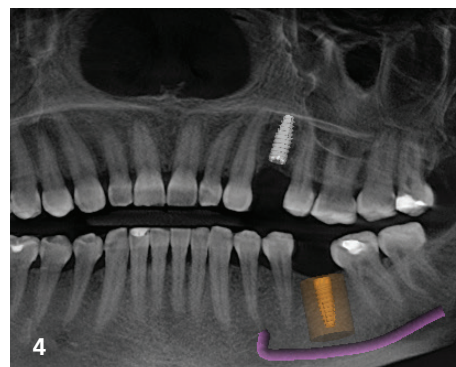
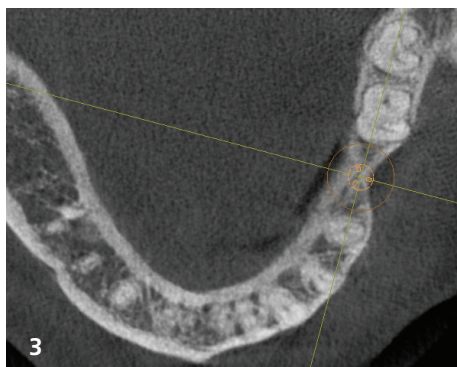
In addition to an adequate bone situation, sufficient attached and keratinised mucosa is important for long-term success in order to avoid peri-implantitis developing and to prevent aesthetic losses or limitations of the prosthetic restoration.⁴⁻⁶ If the bone volume is insufficient, bone augmentation or regenerative measures are often necessary. A wide variety of methods, measures and techniques are used for this purpose, for both horizontal and vertical defects,⁷ such as augmentation of buccal or horizontal defects with granules of various types. In combination with a membrane, an increase in volume of up to approximately 3 mm can be achieved if indicated.⁸ In our practice, various materials are used for this purpose. When using these materials, it is important to ask oneself whether one wants to perform a volume-stable build-up with very little to no resorption or whether one wants to achieve complete remodelling and reshaping into vital bone using biomimetic materials. In

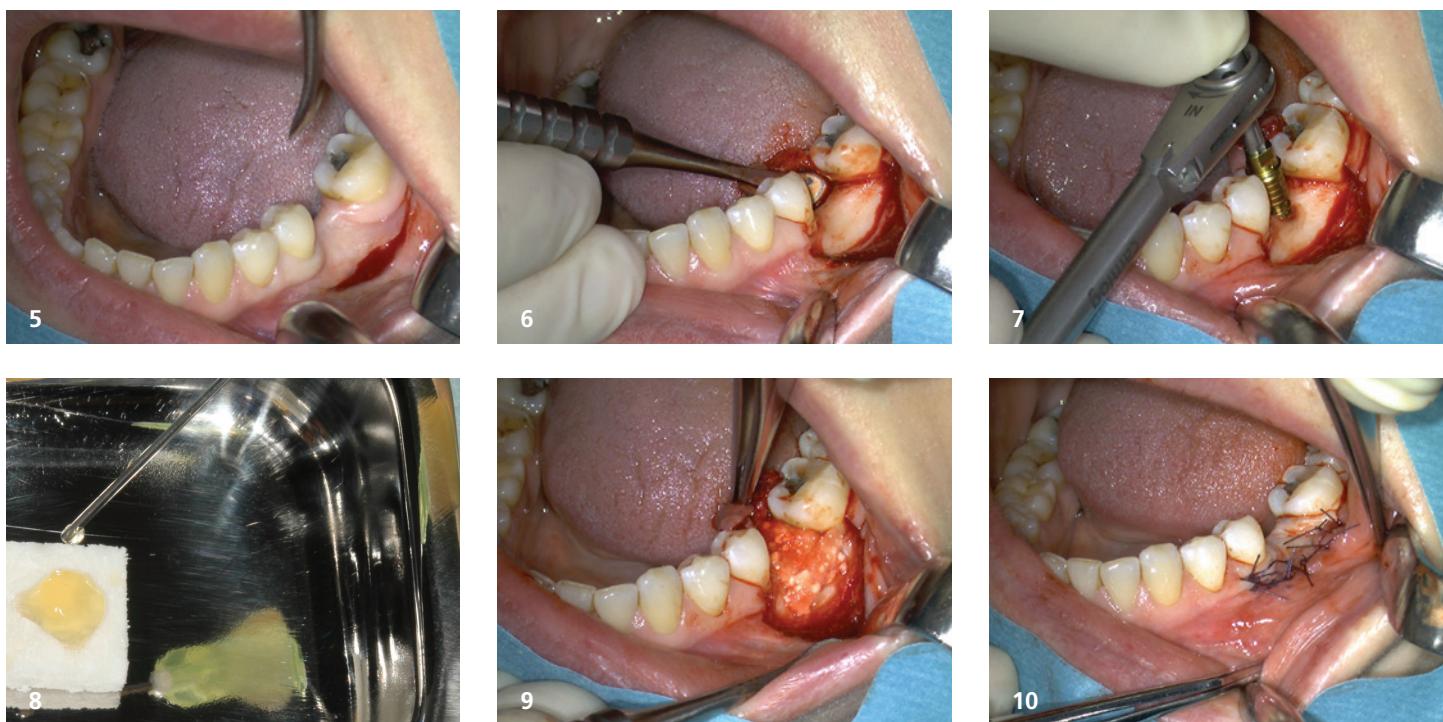
combination with the unavoidable side effect of a controlled but nevertheless present volume loss, the use of biologised materials according to Ghanaati's low-speed centrifugation concept (LSCC) seems to be a promising approach in this regard, and has been increasingly used and observed in practice.^{9, 10}

In the case presented here, a buccal defect was augmented after implantation using a bone regeneration material (a 3D β -tricalcium phosphate collagen matrix; CERASORB Foam, curasan) biologised with platelet-rich fibrin and further covered with fibrin membranes. The intention of this method is to achieve complete remodelling of the inserted material into vital

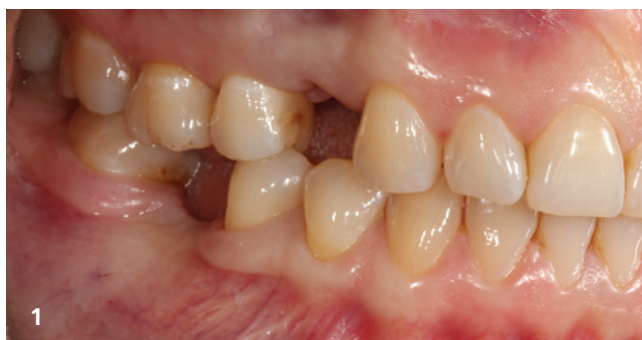

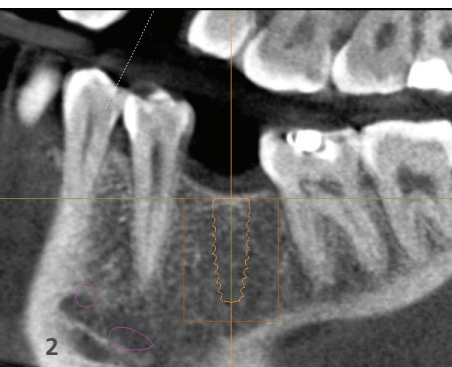Fig. 1: Initial clinical situation in region #36 with a clear buccal contour incision and complete absence of buccal keratinised mucosa. **Figs. 2-4:** CBCT: the transversal and vertical views clearly showed the buccal defect in region #36.





Figs. 5 & 6: Vestibuloplasty modified according to Edlan–Mejchar, lingual mobilisation of the flap and visualisation of the surgical site. **Fig. 7:** Manual final implant positioning to a torque of 25 Ncm². **Fig. 8:** Biologisation and wetting of the CERASORB Foam with injectable platelet-rich fibrin according to the low-speed centrifugation concept protocol. **Fig. 9:** Gentle adaptation of the easily mouldable CERASORB Foam to the defect situation in two layers with medium gentle compression. **Fig. 10:** Layering of two fibrin membranes, plastic coverage of the surgical area.

bone and to support the regeneration of a buccal defect under controlled volume loss.

Case presentation

A healthy 49-year-old female patient presented to our practice with missing teeth #24 and 36 and a request for single-tooth implant restorations. In region #24, the bone and soft-tissue situation was clinically and radiographically adequate. Since this case report deals with the restoration of the implant in region #36, region #24 will not be discussed further. In region #36, there was a considerable bone and soft-tissue defect buccally (Fig. 1). Pre-implant planning using CBCT (Orthophos XG 3D, Dentsply Sirona) was performed to evaluate the situation (Figs. 2–4). After evaluation of the CBCT scan and planning, an implant with a diameter of 3.8mm and a length of 11.0mm was selected for region #36.

A few weeks later, the implant was placed under local anaesthesia with simultaneous lateral augmentation. In order to provide sufficient plastic coverage of the augmentation area and the surgical area later, a vestibuloplasty modified according to Edlan–Mejchar was performed. An arch-shaped incision was made buccally. A split-thickness flap was formed crestally and then a horizontal periosteal incision was made. The split-thickness flap formed in this way (combined mucosa and mucoperiosteal flap) was mobilised lingually, and the surgical

site was visualised. This revealed a homogeneously structured bone of Class D1 quality (Figs. 5 & 6). After marking and defining of the implant position, the implant site was prepared according to the defined drilling protocol, and the implant was placed to a torque of 25 Ncm² (Fig. 7).

After implant placement, the buccal bone defect or the buccal contour defect was augmented with the collagen matrix. In the hydrated and biologised state in which it was used, the matrix can be excellently shaped and adapted to the defect situation with light to medium compression (Fig. 8). The 3D matrix was adapted and attached to the defect situation in two parts, one layer in the vertical direction and one layer in the horizontal direction. The reason for this two-layer approach was the calculated and deliberately controlled resorption of the material described at the beginning, in order to ensure sufficient material for the remodelling process of the bone and the soft tissue. At the end of the procedure, two fibrin membranes were placed on the augmentation area, and the surgical area was sutured plastically tight (Figs. 9 & 10). At the end of the operation, a radiographic postoperative control was performed with a dental panoramic tomogram (Fig. 11).

Healing was pain-free and observation of the course of healing showed completely irritation-free, stable tissue (Fig. 12). After about four months, the implant was uncovered under local anaesthesia. Clinically, the peri-implant bone was sufficiently dimensioned, firm and stable; there was an estimated volume

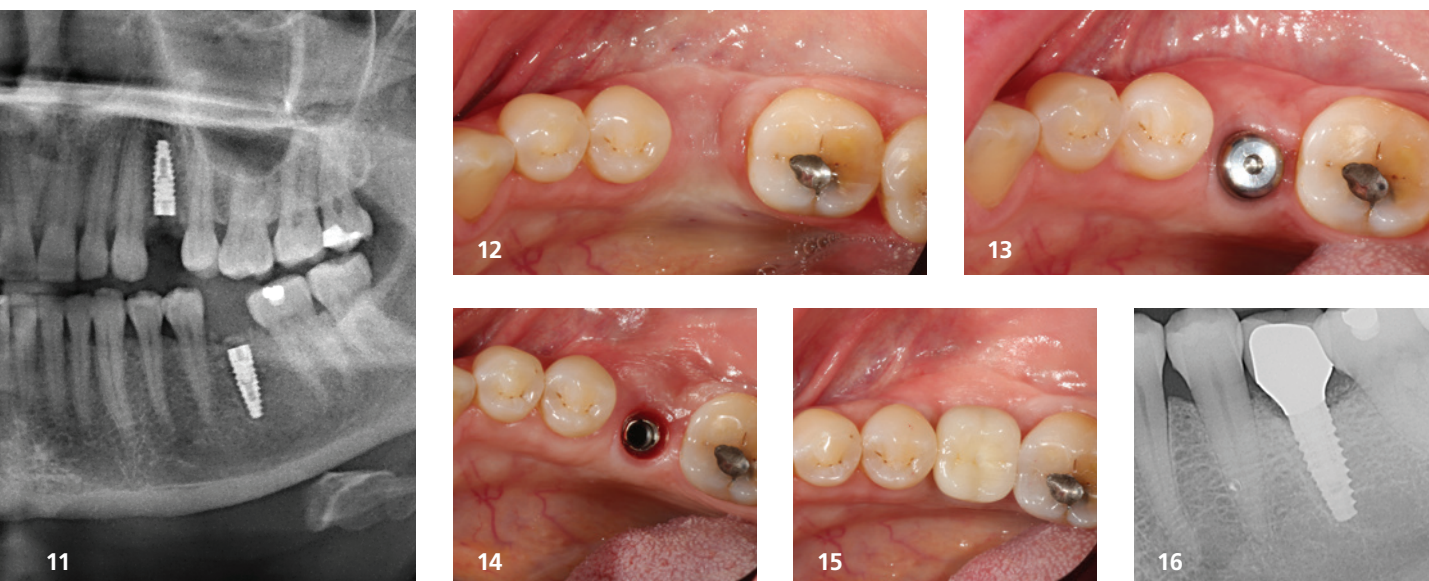


Fig. 11: Postoperative dental panoramic tomogram. **Fig. 12:** Observation of the course of healing found completely irritation-free, stable and pain-free conditions. **Fig. 13:** Exposure of the implant after about four months and inserted healing abutment. **Fig. 14:** Individually shaped mucosa immediately before definitive restoration. **Fig. 15:** After seating of the ceramic crown. **Fig. 16:** Final radiograph.

gain of 2 mm, especially in the buccal region; and there was a significant volume gain in the soft tissue (Fig. 13). After a further four weeks, the final prosthetic restoration of a ceramic crown on a customised zirconia abutment was made, the fit, aesthetics and occlusion were checked and the final radiograph was taken (Figs. 14–16). After six months, a final clinical check and evaluation of the clinical situation were carried out. Stable, irritation-free soft-tissue conditions and, above all, sufficiently dimensioned, stable, attached and keratinised mucosa were still evident buccally.

Conclusion

With the treatment protocol presented, simultaneous augmentation in implantology can be performed predictably. Using individual concepts specifically adapted to the situation, buccal ridge defects can be treated successfully and regeneratively using biologised bone substitute materials. The special 3D matrix structure of CERASORB Foam enables simple and safe handling and very good adaptation to the bony defect. Even though histological evidence of bone regeneration and augmentation was not provided in this clinical case report, the soft-tissue situation showed a clear contour improvement clinically. The combination of the bone substitute with its special collagen matrix and its biomimetic properties, biologised according to the LSCC protocol, as well as the surgical soft-tissue techniques used contributed to this clinically stable and adequately dimensioned situation. In combination with the unavoidable side effect of controlled volume loss, the use of biologised materials seems to be a promising approach in this regard and is increasingly being applied and gaining growing attention in practice.

About...

Dr Haki Tekyatan



is a Germany-based dentist who specialises in implant dentistry and oral surgery. He is currently in private practice in the German city of Simmern.

Author details



Literature



Contact address

Dr Haki Tekyatan

info@dr-tekyatan.de

www.dr-tekyatan.de